

# Interactive CardioVascular and Thoracic Surgery

## **Autologous platelet-rich plasma: effect on sternal healing in the sheep model**

Ignacio Gallo, Alberto Sáenz, Edurne Artiñano and Javier Esquide

*Interact CardioVasc Thorac Surg* 2010;11:223-225; originally published online Jun 30, 2010;

DOI: 10.1510/icvts.2010.237776

The online version of this article, along with updated information and services, is located on the World Wide Web at:

<http://icvts.ctsnetjournals.org/cgi/content/full/11/3/223>

*Interactive Cardiovascular and Thoracic Surgery* is the official journal of the European Association for Cardio-thoracic Surgery (EACTS) and the European Society for Cardiovascular Surgery (ESCVS). Copyright © 2010 by European Association for Cardio-thoracic Surgery. Print ISSN: 1569-9293.

## Work in progress report - Experimental

# Autologous platelet-rich plasma: effect on sternal healing in the sheep model

Ignacio Gallo<sup>a,\*</sup>, Alberto Sáenz<sup>a</sup>, Edurne Artiñano<sup>b</sup>, Javier Esquide<sup>a</sup>

<sup>a</sup>Department of Cardiac Surgery, Policlínica Gipuzkoa, P.O. Box 5076, 20018 San Sebastian, Spain

<sup>b</sup>Department of Pathology, Policlínica Gipuzkoa, San Sebastian, Spain

Received 14 March 2010; received in revised form 9 June 2010; accepted 9 June 2010

### Abstract

Postcardiotomy sternal wound complications remain challenging. We looked at the effects of plasma rich in growth factors (PRGF) as an agent on sternal bone healing. In 24 female sheep, a median sternotomy was surgically created. In 12 of them (group control) the sternum was closed with three figure-of-eight wires. In 12 (group PRGF) three clots of autologous PRGF were applied over the sternum after its closure in the same manner as the control group. All sheep were killed at the nine-week follow-up. The sternum and the surrounding soft tissue was removed and fixed in formaldehyde. Transversal sections of the bone were obtained, decalcified and stained with hematoxylin and eosin. In the control group, we found extensive cartilaginous areas. In the PRGF group, the presence of trabecular bone tissue was common, with formation of hematopoietic medullary tissue. The process of new bone formation was accelerated in the PRGF group at the nine-week follow-up. In contrast, in the control group, the presence of cartilaginous tissue was the most common finding.

© 2010 Published by European Association for Cardio-Thoracic Surgery. All rights reserved.

**Keywords:** Animal model; Blood constituents; Chest wall; Mediastinal infection; Sternum; Wound healing

### 1. Introduction

Median sternotomy is the most common access for open heart surgery. Sternal wound complications, including dehiscence and infection, remain challenging and occur in 1%–3% of patients undergoing cardiac surgery [1, 2], leading to a variable mortality rate ranging from 14% to 47% [3].

The pathogenesis is not yet clearly defined, and various factors have been involved as potential causes, including obesity, uni- or bilateral harvesting of the internal mammary artery, diabetes mellitus, corticosteroid treatment, advanced age, female sex, active smoking, chronic lung disease, reoperation for bleeding or use of blood products, extensive use of electrocautery, the use of bone wax, hair removal with razor, and prolonged procedural times [4, 5]. Also the use of intra-aortic balloon pump, prolonged postoperative mechanical ventilation and pulmonary infection increase the risk of a mediastinal infection [6].

Several techniques have been proposed for maximizing sternal stability in high-risk patients [7–12].

Clinical uses of plasmatic growth factors have been reported in the treatment of articular cartilage avulsion, arthroscopic surgery, dentistry and oral-maxillofacial surgery, and muscular tear [13–15].

The aim of this experimental study in the growing sheep model, is to evaluate the feasibility of using autologous

plasma rich in growth factors (PRGF) to accelerate the wound sternal healing.

### 2. Materials and methods

#### 2.1. Experimental animals

In 24 female latxa black-faced sheep weighing 18–29 kg (mean, 22.4 ± 3.61 kg), a median sternotomy was surgically created. In group I (12 animals, group PRGF), after closure of median sternotomy with three figure-of-eight steelwires (one in the manubrium and two in the body), three cylinders of PRGF were applied over the sternal wound, covered by the subcutaneous and dermal tissue (Fig. 1). In group II (12 animals, group control) only three figure-of-eight steelwires were used to close the sternum.

All animals received humane care in compliance with the European Convention on Animal Care.

#### 2.2. Anesthetic and postoperative management

Anesthesia was induced by injecting intravenously propofol (Diprivan) into the left/right jugular vein at a concentration of 6 mg/kg. The intubation was performed with an endotracheal probe (no. 7). Ventilation was ensured with a Narkomed 2C (Dräger Medical, Telford, PA, USA) respirator by the use of the following parameters: a volume of 10 ml/kg, a frequency of 24 breaths/min, and a inspired oxygen fraction of 60%. Anesthesia was maintained by inhalation 1%–2% of isoflurane. Postoperative management

\*Corresponding author. Tel./fax: +34 943 212872.

E-mail address: igallo@hemociru.com (I. Gallo).

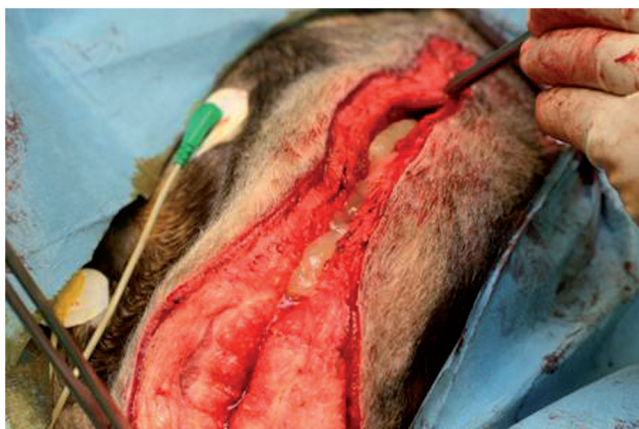

Fig. 1. After closure of median sternotomy, three cylinders of PRGF were applied over the sternal wound, being covered with the subcutaneous and dermal tissue.

of the sheep consisted of cefazolin injected intramuscularly at 1 g/day over five days. Analgesia was guaranteed using metamizol at 2 g intramuscularly every 12 h over five days.

### 2.3. Preparation of PRGF

Forty millimeters of venous blood were withdrawn from the jugular vein after administration of anesthesia. Blood was collected in 5-ml tubes containing 3.8% trisodium citrate, then centrifuged at 1800 rpm for 8 min (PRGF System II, BTI, Vitoria-Gasteiz, Spain). The 1 ml fractions located immediately above the erythrocytes were collected from each tube and transferred to sterile tubes. Care was taken to avoid collection from the buffy coat. Fifty microliters of  $\text{CaCl}_2$  at 10% (w/v) were added per 1-ml fraction of platelet-enriched plasma, and the tubes were put to heat until cylindrical clots were obtained in a few minutes (Fig. 2).

### 2.4. Histology

All sheep were killed nine weeks after surgery. The sternum and the surrounding soft tissue were removed and fixed in 4% (w/v) neutral buffered formalin pH 7.2–7.4 [Diapath S.r.l., Martinengo (BG), Italy]. Transversal sections of the bone were obtained, and were decalcified using JT Baker rapid decalcifier (Mallinckrodt Baker B.V., Deventer, Holland). The sections were embedded in diawax, 56°–58° [Diapath S.p.s., Matinengo (BG), Italy] and sectioned to yield 3- $\mu\text{m}$ -thick slices. The sections were stained with hematoxylin and eosin. The pathologist did the comparative evaluation as a blinded examiner.

### 3. Results

No early superficial wound complications were observed, although the sheep was lies at rest in prone decubitus and over a not totally clean floor.

All sheep were killed using a euthanasia solution. The sternum was removed and no dehiscences were observed, maintaining a stable consistency.



Fig. 2. Three cylindrical clots were prepared to implant over the sternal sheep wound.

By histological analysis with hematoxylin and eosin stain, in the control group we found extensive cartilaginous areas with the presence of surrounding endochondral ossification, and new vessels as well as formation of 'woven bone' (soft callus) (Fig. 3).

In the PRGF group, the presence of trabecular bone tissue was common, with the formation of hematopoietic medullary tissue (hard callus), as an indication of most advanced reparative phase (Fig. 4). Occasionally, small areas of cartilaginous tissue with endochondral ossification were present.

### 4. Discussion

A median sternotomy is a common approach to the heart during cardiac surgical procedures. The ability to predict sternal complications after an operation as common as open heart surgery has important ramifications for patients, caregivers, medical research, and the health care industry.

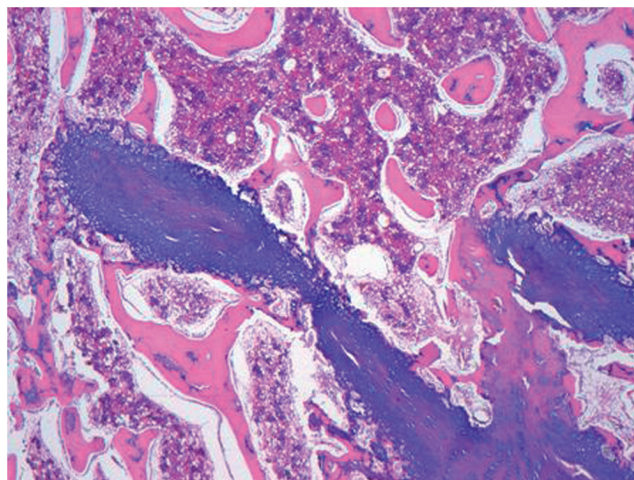


Fig. 3. Cartilaginous tissue (blue stain) with endochondral ossification (pink and red stain) in a non-treated sheep. (H&E; original magnification, 100 $\times$ .)

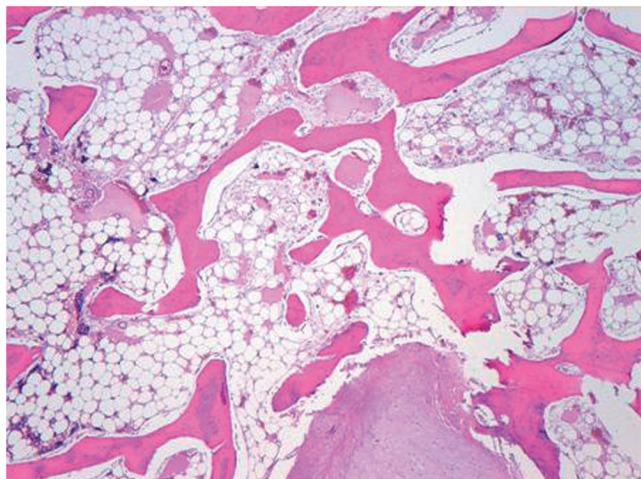


Fig. 4. Matured bone tissue in a PRGF treated sheep. Trabecular bone (pink stain) with adipous tissue and hematopoietic medullary tissue (with stain). (H&E; original magnification, 100 $\times$ .)

The incidence of sternal wound complications have not changed since the 1980s, although major changes occurred in patients at risk, the population became older and sicker. Many references with this subject appear every year in the cardiovascular literature and it is still a problem in the field of cardiac surgery. Most of these references focus on the treatment of the complication, instead of the prevention on its appearance.

Recent reports suggest that the process of healing may be improved by growth factors, which are small proteins synthesized both by local cells at the injury site and by infiltrated blood inflammatory cells. These factors stimulate cell proliferation, migration, differentiation, and matrix synthesis and can affect chondrocyte metabolism, chondrogenesis, and improve bone healing [13].

Our work is based on the use of an autologous PRGF obtained from the sheep's own blood by means of a simple procedure. Upon activation, platelets aggregate producing a clot, and secrete a variety of cytokines, including adhesive proteins and growth factors, such as platelet-derived, transforming growth factor beta, vascular endothelial growth factor, basic fibroblast growth factor, insulin-like growth factor, and epidermal growth factor. These substances act on local cells inducing specific responses and modulate wound healing.

In our experience with the sternal healing in the sheep model, the process of new bone formation was accelerated in the PRGF group at the nine-week of follow-up. In contrast, in the control group, the presence of cartilaginous tissue was the most common finding.

Further studies in order to know the advantages of this method in the human clinical setting will be necessary.

#### Acknowledgments

The authors want to thank to Ina Beltran de Heredia for her excellent animal care; to Ana Martínez-Peñuela, Ignacio Pérez-Moreiras, Iñaki Larrabide, Ignacio Camacho, Ana Aguirre, Gema Alonso, Noemi Gutierrez and Mar Artal who performed the monitoring necessary for this study.

#### References

- [1] Fokin A, Robicsek F, Masters T, Fokin A, Reames M, Anderson J. Sternal nourishment in various conditions of vascularization. *Ann Thorac Surg* 2005;79:1352–1357.
- [2] Molina JE. Evaluation and operative technique to repair isolated sternal fractures. *J Thorac Cardiovasc Surg* 2005;130:445–448.
- [3] Dimarakis I, Oswal D, Nair U. Single stage sternal reconstruction using titanium mesh for dehiscence following open-heart surgery. *Interact CardioVasc Thorac Surg* 2005;4:49–51.
- [4] Kiessling A, Isgro F, Weisse U, Moltner A, Saggau W, Boldt J. Advanced sternal closure to prevent dehiscence in obese patients. *Ann Thorac Surg* 2005;80:1537–1539.
- [5] Athanasiou T, Crossman MC, Asimakopoulos G, Cherian A, Weerasinghe A, Glenville B, Casula R. Should the internal thoracic artery be skeletonized? *Ann Thorac Surg* 2004;77:2238–2246.
- [6] Newman LS, Szezukowski LC, Bain RP, Perlino CA. Suppurative mediastinitis after open heart surgery. A case control study of risk factors. *Chest* 1988;94:546–553.
- [7] Robicsek F, Fokin A. Search for a better mousetrap: the guest for an ideal method of sternal closure. *Eur J Cardiothorac Surg* 2008;33:767–768.
- [8] Schimmer C, Sommer S, Bensch M, Leyh R. Primary treatment of deep sternal wound infection after cardiac surgery: a survey of German heart surgery centers. *Interact CardioVasc Thorac Surg* 2007;6:708–711.
- [9] Hamaji M, Sakaguchi Y, Matsuda M, Kono S. Reinforced closure of the sternum with absorbable pins for high-risk patients. *Interact CardioVasc Thorac Surg* 2009;9:559–561.
- [10] Muehrcke D, Shimp WM, Aponte-Lopez R. Calcium phosphate improve density when used in osteoporotic sternums. *Ann Thorac Surg* 2009;88:1658–1661.
- [11] Snyder C, Graham L, Byers R, Holman W. Primary sternal plating to prevents sternal complications after cardiac surgery: early experience and patterns of failure. *Interact CardioVasc Thorac Surg* 2009;9:763–766.
- [12] Friberg Ö, Dhalin L, Källman J, Kihlström E, Söderquist B, Svedjeholm R. Collagen-gentamicin implant for prevention of sternal wound infection; long-term follow-up of effectiveness. *Interact CardioVasc Thorac Surg* 2009;9:454–458.
- [13] Sanchez M, Azofra J, Anitua E, Andia I, Padilla S, Santisteban J, Mujika I. Plasma rich in growth factors to treat an articular cartilage avulsion: a case report. *Med Sci Sports Exerc* 2003;35:1648–1652.
- [14] Anitua E. Plasma rich in growth factors: preliminary results of use in the preparation of future sites for implants. *Int J Oral Maxillofac Implants* 1999;14:529–535.
- [15] Loo W, Lee D, Soon M. Plasma rich in growth factors to treat adductor longus tear. *Ann Acad Med* 2009;38:733–734.

**Autologous platelet-rich plasma: effect on sternal healing in the sheep model**  
Ignacio Gallo, Alberto Sáenz, Edurne Artiñano and Javier Esquide  
*Interact CardioVasc Thorac Surg* 2010;11:223-225; originally published online Jun 30,  
2010;  
DOI: 10.1510/icvts.2010.237776

**This information is current as of August 12, 2011**

<b>Updated Information &amp; Services</b>	including high-resolution figures, can be found at: <a href="http://icvts.ctsnetjournals.org/cgi/content/full/11/3/223">http://icvts.ctsnetjournals.org/cgi/content/full/11/3/223</a>
<b>References</b>	This article cites 15 articles, 12 of which you can access for free at: <a href="http://icvts.ctsnetjournals.org/cgi/content/full/11/3/223#BIBL">http://icvts.ctsnetjournals.org/cgi/content/full/11/3/223#BIBL</a>
<b>Permissions &amp; Licensing</b>	Requests to reproducing this article in parts (figures, tables) or in its entirety should be submitted to: <a href="mailto:icvts@ejcts.ch">icvts@ejcts.ch</a>
<b>Reprints</b>	For information about ordering reprints, please email: <a href="mailto:icvts@ejcts.ch">icvts@ejcts.ch</a>

# Interactive CardioVascular and Thoracic Surgery